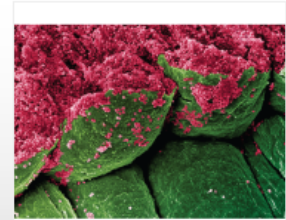
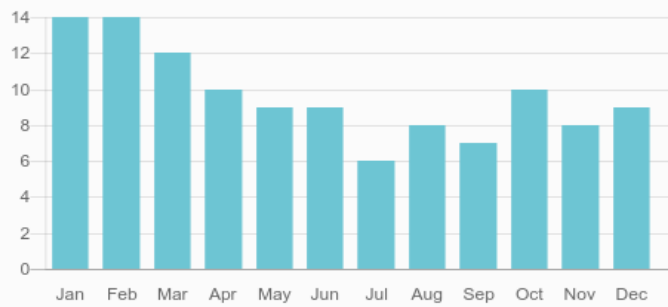


Case Reports in Ophthalmological Medicine

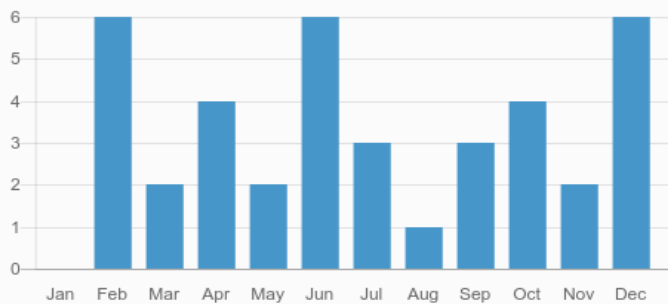


Case Reports in
Ophthalmological Medicine

Submissions



Publications



166.0

Total authors



39

Total published articles

90
DAYS

Average time from
submission to
acceptance

30
DAYS

Average time from
acceptance to
publication

116

41

Total submitted articles

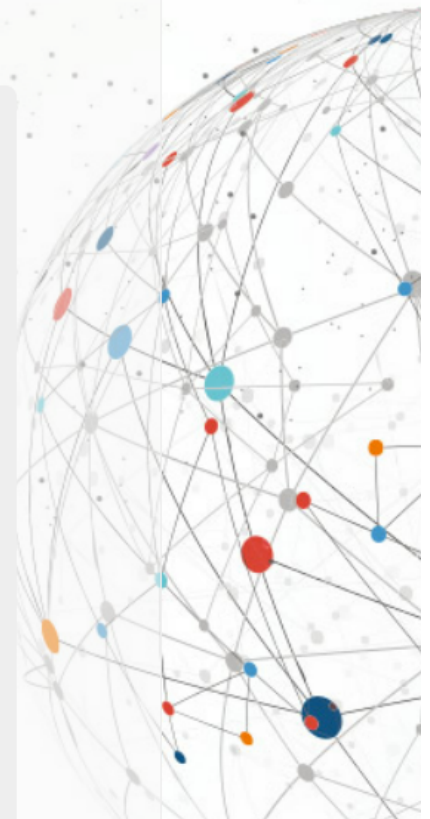Total accepted articles

Most Viewed Articles

Article	Views
BRANCH RETINAL ARTERY OCCLUSION FOLLOWING DENTAL EXTRACTION	4,236
Isolated Multiple Pigment Epithelial Detachments with Unknown Cause	3,902
Management of a traumatic flap dislocation seven years post LASIK	2,532
Eyelid edema: A rare cause of a common sign	1,973
CONVERGENCE INSUFFICIENCY / DIVERGENCE INSUFFICIENCY CONVERGENCE EXCESS / DIVERGENCE EXCESS: SOME FACTS AND FICTIONS	1,948
Congenital upper eyelid coloboma. Clinical and surgical management	1,399
VISUAL FIELD DEFECT AFTER CARDIAC SURGERY: THE STRIKING ROLE OF INTERDISCIPLINARY COLLABORATION	1,349
RECURRENT BILATERAL OCCIPITAL INFARCT WITH CORTICAL BLINDNESS AND ANTON SYNDROME	1,274
A case of conjunctival amyloidosis with repeated subconjunctival hemorrhage	1,094
LATE STAGE OF CORNEAL DECOMPENSATION CAUSED BY PROGRESSIVE KERATOCONUS - CAN WE TREAT IT AND SAVE THE CORNEA?	1,030

Most Viewed Special Issue Articles

Article	Views
Optical Coherence Tomography Angiography	890
Evolution of Choroidal Neovascularization Due to Presumed Ocular Histoplasmosis Syndrome on Multimodal Imaging Including Optical Coherence Tomography Angiography	587
Ocular coherence tomography angiography of retinal arterial macroaneurysm before and after treatment	581
Optical coherence tomography angiography of combined central retinal artery and vein occlusion	541
Optical coherence tomography angiography of Purtscher retinopathy after severe traffic accident in 16-year old boy	509
Cilioretinal artery occlusion combined with central retinal vein occlusion: What is the best imaging modality for the follow-up?	471
Sequential Observations of Conversion from Non-ischemic to Ischemic Central Retinal Vein Occlusion Using Optical Coherence Tomography Angiography	447



Optical coherence tomography angiography of macular telangiectasia type 2 with associated subretinal neovascular membrane	413
Optical Coherence Tomography Angiography (OCT-A) of Punctate Inner Choroidopathy	331
Multimodal Images of Acute Central Retinal Artery Occlusion	325

Key Indexes

[View all abstracting and indexing databases for this journal](#)