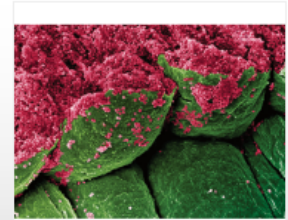
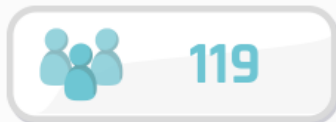
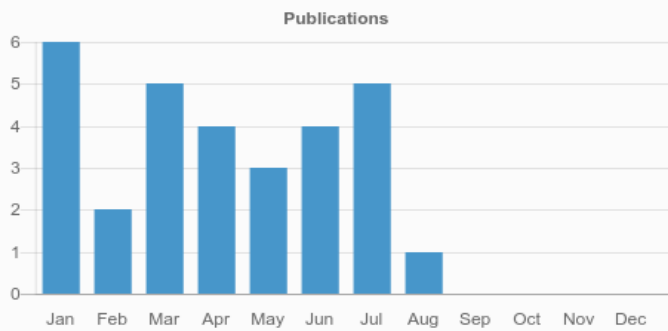
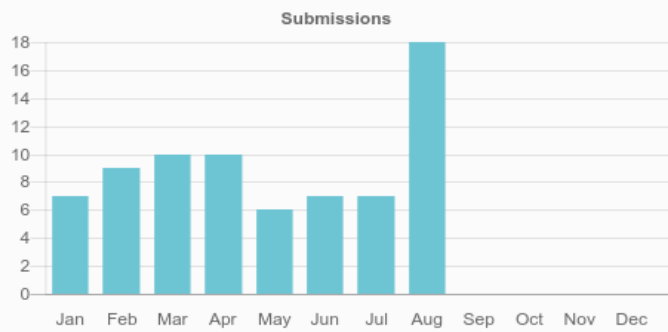

Case Reports in Ophthalmological Medicine




Case Reports in Ophthalmological Medicine



Total authors




Total published articles



Average time from submission to acceptance



Average time from acceptance to publication

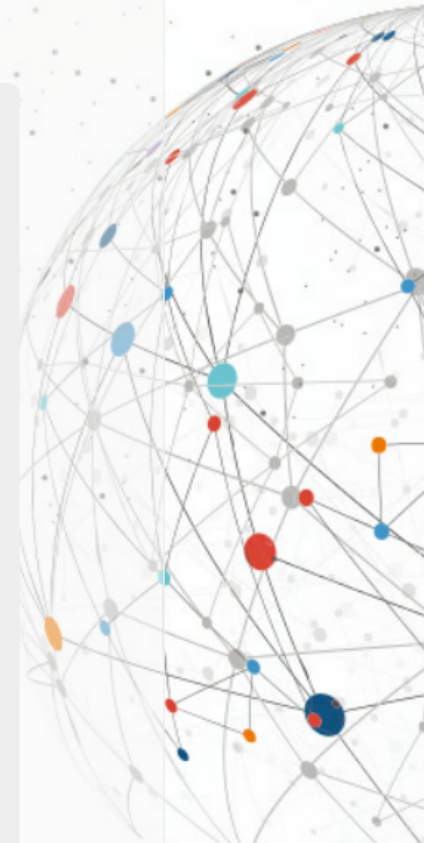


Most Viewed Articles

Article	Views
BRANCH RETINAL ARTERY OCCLUSION FOLLOWING DENTAL EXTRACTION	3,249
Eyelid edema: A rare cause of a common sign	2,629
Isolated Multiple Pigment Epithelial Detachments with Unknown Cause	2,233
Management of a traumatic flap dislocation seven years post LASIK	1,575
VISUAL FIELD DEFECT AFTER CARDIAC SURGERY: THE STRIKING ROLE OF INTERDISCIPLINARY COLLABORATION	1,470
Absent foveal pit, also known as fovea plana, in a child without associated ocular or systemic findings	1,458
Periorbital Edema Secondary to Positive Airway Pressure Therapy	1,444
CONVERGENCE INSUFFICIENCY / DIVERGENCE INSUFFICIENCY CONVERGENCE EXCESS / DIVERGENCE EXCESS: SOME FACTS AND FICTIONS	1,383
Congenital upper eyelid coloboma. Clinical and surgical management	1,191
RECURRENT BILATERAL OCCIPITAL INFARCT WITH CORTICAL BLINDNESS AND ANTON SYNDROME	941

Most Viewed Special Issue Articles

Article	Views
Cilioretinal artery occlusion combined with central retinal vein occlusion: What is the best imaging modality for the follow-up?	402
Optical coherence tomography angiography of combined central retinal artery and vein occlusion	372
Sequential Observations of Conversion from Non-ischemic to Ischemic Central Retinal Vein Occlusion Using Optical Coherence Tomography Angiography	344
Evolution of Choroidal Neovascularization Due to Presumed Ocular Histoplasmosis Syndrome on Multimodal Imaging Including Optical Coherence Tomography Angiography	329
Ocular coherence tomography angiography of retinal arterial macroaneurysm before and after treatment	288
Optical coherence tomography angiography of macular telangiectasia type 2 with associated subretinal neovascular membrane	212
Optical Coherence Tomography Angiography	212



Optical coherence tomography angiography of Purtscher retinopathy after severe traffic accident in 16-year old boy	212
Optical Coherence Tomography Angiography (OCT-A) of Punctate Inner Choroidopathy	212
Optical coherence tomography angiography of two choroidal nevi variants	199

Key Indexes

[View all abstracting and indexing databases for this journal](#)

