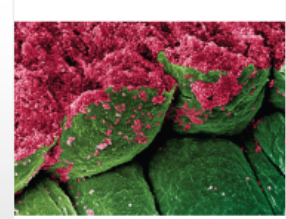
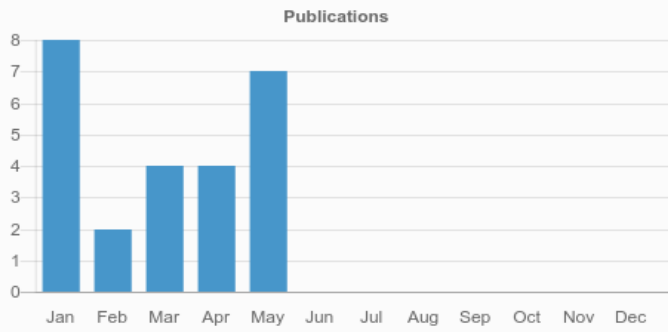
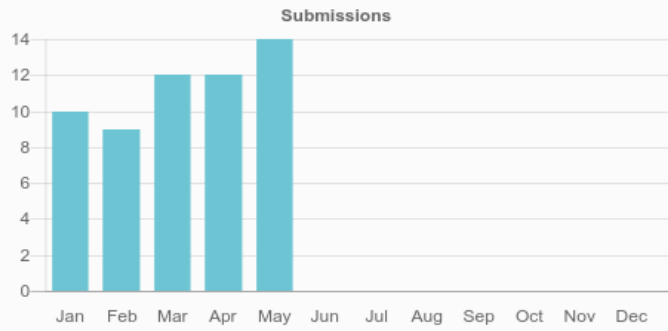


Case Reports in Ophthalmological Medicine



Case Reports in
Ophthalmological Medicine



117

Total authors



25

Total published articles

98
DAYS

Average time from
submission to
acceptance

28
DAYS

Average time from
acceptance to
publication

57

32

Total submitted articles

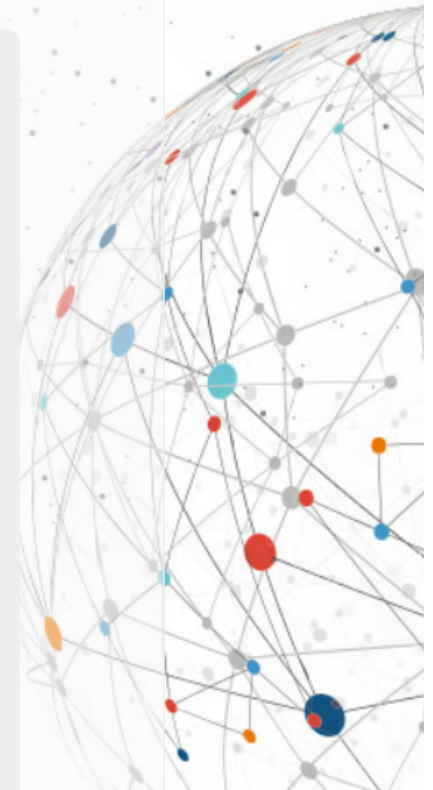
Total accepted articles

Most Viewed Articles

Article	Views
BRANCH RETINAL ARTERY OCCLUSION FOLLOWING DENTAL EXTRACTION	3,375
Eyelid edema: A rare cause of a common sign	2,560
Periorbital Edema Secondary to Positive Airway Pressure Therapy	1,984
Isolated Multiple Pigment Epithelial Detachments with Unknown Cause	1,545
CONVERGENCE INSUFFICIENCY / DIVERGENCE INSUFFICIENCY CONVERGENCE EXCESS / DIVERGENCE EXCESS: SOME FACTS AND FICTIONS	1,507
Unilateral eyelid edema as initial sign of orbital sarcoidosis	1,293
Congenital upper eyelid coloboma. Clinical and surgical management	1,258
VISUAL FIELD DEFECT AFTER CARDIAC SURGERY: THE STRIKING ROLE OF INTERDISCIPLINARY COLLABORATION	1,257
Bilateral Trichotillomania of Eyelashes Triggered by Anxiety Due to Nocturnal Enuresis	1,188
Giant Squamous Cell Papilloma of the Eyelid - Diagnostic and Therapeutic Challenges.	1,115

Most Viewed Special Issue Articles

Article	Views
Sequential Observations of Conversion from Non-ischemic to Ischemic Central Retinal Vein Occlusion Using Optical Coherence Tomography Angiography	510
Cilioretinal artery occlusion combined with central retinal vein occlusion: What is the best imaging modality for the follow-up?	292
Optical coherence tomography angiography of combined central retinal artery and vein occlusion	221
Optical coherence tomography angiography of macular telangiectasia type 2 with associated subretinal neovascular membrane	203
Ocular coherence tomography angiography of retinal arterial macroaneurysm before and after treatment	202
Optical coherence tomography angiography of two choroidal nevi variants	200
Multimodal imaging analysis in a case with congenital fovea-involving retinal macrovessel and excellent visual acuity	163



Evolution of Choroidal Neovascularization Due to Presumed Ocular Histoplasmosis Syndrome on Multimodal Imaging Including Optical Coherence Tomography Angiography	150
Optical Coherence Tomography Angiography (OCT-A) of Punctate Inner Choroidopathy	146
Multimodal Images of Acute Central Retinal Artery Occlusion	141

Key Indexes

[View all abstracting and indexing databases for this journal](#)